

## A REVIEW ON SHEEP PULMONARY ADENOCARCINOMA

Review

AUTHOR: Daniel Teshome Gebeyehu

June 2017

Wollo University, School Of Veterinary Medicine  
May, 2017, Dessie, Ethiopia  
Phone: +251913594781

**CORRESPONDENCE AUTHOR**

Daniel Teshome Gebeyehu  
Email: dteshome11@Gmail.Com

**CONFLICTS OF INTEREST**

There are no conflicts of interest for any of the authors.

Received Date: 8<sup>th</sup> May 2017

Accepted Date: 3<sup>rd</sup> June 2017

Published Date: 13<sup>th</sup> June 2017

Copy rights: © This is an  
Open access article distribut-  
ed under the terms of Crea-  
tive Commons Attribution 4. 0  
International License.

**ABSTRACT**

Ovine pulmonary adenocarcinoma (OPA), also known as jaagsiekte, is a transmissible lung tumor of sheep caused by jaagsiekte sheep retrovirus (JSRV). OPA is first described in the early 19<sup>th</sup> century; however, it has still not been possible to devise effective methods for controlling its spread and it remains an important problem in most countries where sheep are farmed. JSRV induces neoplastic transformation of alveolar and bronchiolar secretary epithelial cells and the resulting tumors can grow to occupy a significant portion of the lung. Tumor growth is frequently accompanied by the overproduction of fluid in the lung, which further compromises normal respiration. Lungs develop few multifocal consolidated slightly elevated gray to white masses. The presence of Jaagsiekte sheep retrovirus (JSRV) is usually demonstrated in the lungs by immunohistochemistry. JSRV protein is detected in all tumor epithelial cells, histologically normal alveolar type II cells, and few bronchiolar epithelial cells, alveolar macrophages, lymphocytes, and plasma cells. The period between infection and the appearance of clinical signs may be several months or years and many JSRV infected sheep do not exhibit clinical signs at all during their lifespan. This allows the spread of OPA into new flocks through contact with infected but apparently normal animals. This is due to the absence of an immunological response to JSRV in infected animals, which has hindered the development of serological diagnostic tests and vaccines. It can cause about 80% loss of flock for first exposure and 20% for endemic area.

**Keywords:** Adenocarcinoma, Jaagsiekte, Sheep, Lung, Tumor, Betaretrovirus

**INTRODUCTION**

Ovine pulmonary adenocarcinoma is a naturally occurring adenocarcinoma of sheep. This disease was first recognized in South Africa in the 19th century as a cause of respiratory distress in sheep when they were herded. The Afrikaans name “jaagsiekte” was coined from “driving” (jaag) and “sickness” (ziekte) reflecting the tendency of diseased sheep to lag behind the flock during herding (Palmarini *et al.*, 1996).

OPA is a contagious viral disease of sheep that results in pulmonary neoplasia in some animals. The economic impact can be significant: up to 80% of the flock can be lost upon first exposure to the virus, with continuing losses that may be as high as 20% each year in some flocks. Excluding this disease from a flock is difficult, in part because no diagnostic test can detect animals in the preclinical stage. No effective treatment or vaccine is available, and eradication is challenging. Currently, ovine pulmonary adenomatosis exists in most sheep-raising areas of the world (CFSPH, 2009).

Ovine pulmonary adenocarcinoma (OPA), also known as ovine pulmonary adenomatosis, and ovine pulmonary carcinoma (OPC), is a contagious lung tumor of sheep and, more rarely of goats. It is the most common pulmonary tumor of sheep and occurs in many countries around the world. It is absent from Australia and New Zealand and has been eradicated from Iceland (OIE, 2008).

This disease is not yet reported from Ethiopia. However, this does not mean that Ethiopia is free from OPA. Thus having knowledge about it is very crucial. Therefore the objectives of this seminar paper are:

To review about the immunohistochemical and pathological finding of ovine pulmonary adenocarcinoma.

To summarize, the nature, etiology and effects of OPA.

To indicate the possible control options of OPA.

## 2. ETIOLOGY AND NATURE OF OPA

Ovine pulmonary adenocarcinoma results from infection by Jaagsiekte sheep retrovirus (JSRV), which is also known as the pulmonary adenomatosis virus. This virus is a member of the genus *Beta retrovirus* in the Retroviridae. A number of different viruses have been linked etiologically to OPA, including a herpes virus and lentiviruses that have been propagated from tumor tissue. However, the former does not have an etiological role in OPA and the latter exhibit characteristics of non-oncogenic lentiviruses (Dawson *et al.*, 1985).

It has been demonstrated clearly that OPA is caused by a beta-retrovirus that cannot yet be cultured *in vitro*, but the virus has been cloned and sequenced. The term Jaagsiekte sheep retrovirus (JSRV) is used in referring to this virus (CFSPH, 2009).

### 2.1. Species Affected

Ovine pulmonary adenocarcinoma mainly affects domesticated sheep (*Ovis aries*). Sardinian moufflon (*Ovis musimon*, a species of wild sheep) can also become ill, and a few cases have been reported in domesticated goat (CFSPH, 2009).

### 2.2. Geographic Distribution

Ovine pulmonary adenocarcinoma can be found in sheep-raising countries in Europe, Africa, Asia and America. This disease does not occur in Australia or New Zealand. It has also been eradicated from Iceland (De Las Heras *et al.*, 2000).

### 2.3. Transmission

Ovine pulmonary adenocarcinoma can be transmitted by the respiratory route, probably via aerosols or droplets. Infectious virus occurs in the respiratory exudates of infected sheep. Jaagsiekte sheep retrovirus can be found in tumors, lung fluids, peripheral blood leucocytes and lymphoid organs. Before tumors develop, the virus is detected in lymphoreticular cells. Horizontal transmission has been demonstrated among sheep of all ages, but neonates seem to be particularly susceptible to infection. There is no evidence that *in utero* transmission is significant in the epidemiology of this disease; however, recent studies suggest that JSRV might be spread in milk or colostrums. Jaagsiekte sheep retrovirus does not survive for long periods in the environment (Sanna *et al.*, 2001)

### 2.4. Incubation Period

The incubation period in naturally infected animals is reported to be 6 months to 3 years. It appears to be age-dependent, and is longer in older sheep. In one experiment it has been observed that 1-week-old lambs developed clinical signs in 70 to 74 days, 1-month-old lambs in 92 to 209 days, and 1 to 6 month-old lambs in approximately 160 days or longer. Experimentally infected adult sheep become ill in several months to years (Khan and Line, 2006).

## 3. DIAGNOSTIC TECHNIQUES

At present, diagnosis of OPA relies on clinical and pathological investigations, although polymerase chain reaction (PCR) offers hope for ante-mortem diagnosis of OPA as a flock test. In flocks in which the disease is suspected, its presence must be, at least once, confirmed by histopathological examination of affected lung tissue. For such an examination, it is imperative to take specimens from several affected sites and, if possible, from more than one animal. This is because secondary bacterial pneumonia, which might be the immediate cause of death, often masks the lesions (both macroscopic and microscopic) of the primary disease. In the absence of specific serological tests that can be used for the diagnosis of OPA in live animals, disease control relies on regular flock inspections and prompts culling of suspected cases (OIE, 2008).

### 3.1. Isolation and Identification of the agent

Although ovine herpesvirus-1 (OvHV-1) had been isolated exclusively from OPA tumors, epidemiological studies and experimental infections provide no evidence for a role in the etiology of OPA. The association of retroviruses with OPA has been recognized for several years. Ovine lentiviruses have been isolated on a number of occasions, but these viruses have no etiological role in OPA. For many years, the inability to culture JSRV and the lack of antibodies to the virus in affected sheep impeded the confirmation of this virus as the etiological agent. However, molecular biological techniques provided a key advance, namely, the cloning and sequencing of the 7.5 kb JSRV genome following purification of virions from lung washes of naturally affected sheep (York *et al.*, 1992).

JSRV has been designated as a beta-retrovirus because of its genetic organization and its structural proteins. Although cloned JSRV genes, used as hybridization probes, have revealed a range of homologous endogenous sequences in the genome of both healthy and OPA-affected sheep (Bai *et al.*, 1996; Hecht *et al.*, 1994), JSRV is clearly exogenous and associated exclusively with OPA (Palmarini *et al.*, 1996). JSRV is detected constantly in the lung fluid, tumor, peripheral blood mononuclear cells, and lymphoid tissues of sheep affected by OPA or unaffected in-contact flock mates, and never in sheep from unaffected flocks with no history of the tumor. Full length proviral clones of JSRV have been obtained from OPA tumor DNA and cells. JSRV virus particles, prepared from these clones by transient transfection of a cell line, were used for intratracheal inoculation of neonatal lambs. OPA tumor was induced in the lambs, thus demonstrating that JSRV is the causal agent of OPA (Demartini *et al.*, 2001; Palarini *et al.*, 1999). The sheep genome contains many copies of endogenous viral sequences that are highly related to JSRV. (Palmarini *et al.*, 2004).

#### 3.1.1. Nucleic acid recognition methods

Sequencing of JSRV and endogenous sequences in the sheep genome has led to the development of PCRs that specifically detect JSRV (Bai *et al.*, 1996; Palmarini *et al.*, 1996). Using this sensitive procedure, JSRV has been detected in peripheral blood mononuclear cells of unaffected in-contact sheep from flocks with OPA, as well as experimentally infected lambs (York *et al.*, 1992; Holland *et al.*, 1999) and the bronchoalveolar lavage samples from unaffected in-contact sheep (Voigt, 2007). Longitudinal studies in OPA-affected flocks have shown that lambs become infected at a very early age. A high proportion of animals in these flocks are infected, yet only a minority develops OPA (Caporale *et al.*, 2005; Salvatori *et al.*, 2005).

#### 3.1.2. Animal inoculation

OPA cannot be transmitted to any laboratory animal and can be transmitted to sheep only with material that contains JSRV, such as tumor homogenates, concentrated cell-free lung fluid from natural cases of OPA and virus produced from molecular clones. Following the experimental inoculation of adult sheep, clinical disease develops only after several months or years. In contrast, JSRV infection can be induced in 100% of lambs aged 1–6 months at the time of inoculation and a high proportion of these animals develop clinical signs (62–90%) and lesions (87–100%) of OPA. At this time there is no practical animal inoculation method for the diagnosis of OPA (Salvatori *et al.*, 2004).

#### 3.1.3. Cell culture

There are no permissive cell culture systems for propagation of JSRV. Some cell cultures prepared from the tumors occurring in young lambs can support virus replication for a short period (Jassim *et al.*, 1988; Sharp *et al.*, 1985).

#### 3.1.4. Serological tests

At present, there are no serological laboratory tests to support a clinical diagnosis of OPA in the live animal. JSRV has been associated exclusively with both typical and atypical forms of OPA, but antibodies to this virus have not been detected in the sera of affected sheep, even with highly sensitive assays such as immunoblotting or enzyme linked immunosorbent assay (Ortin, 1997).

A likely explanation is that the sheep are immunologically tolerant of JSRV antigens due to the expression of closely related endogenous JSRV proteins in the fetal thymus during T lymphocyte development and any JSRV-reactive T cells should be recognized as ‘anti-self’ and selectively removed (Griffiths and camps, 2010).

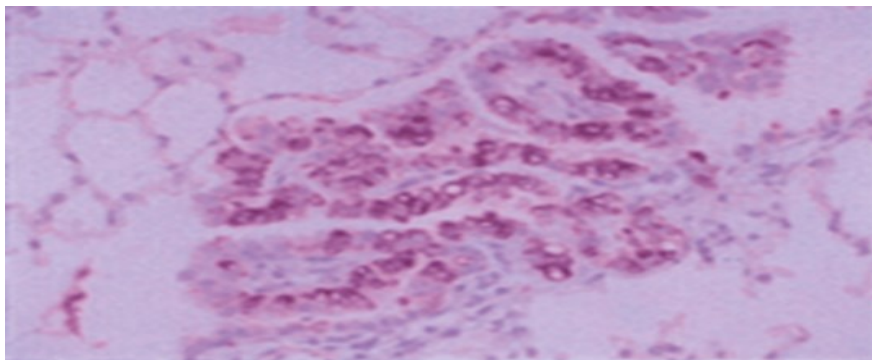
### 3.2. Differential diagnosis

The differential diagnosis includes maedi–visna, bacterial pneumonia and infestation by lungworms. In the early clinical stages, ovine pulmonary adenocarcinoma is difficult to distinguish from many respiratory diseases (De Las Heras *et al.*, 2005).

#### 4. IMMUNOHISTOCHEMICAL CHANGES

Angiogenesis has been suggested to be one of the most important factors underlying tumor growth and invasion. This process involves the action of growth factors including vascular endothelial growth factor (VEGF)-C, basic fibroblast growth factor (bFGF), platelet-derived growth factor (PDGF)-C and its receptor (PDGFR- $\alpha$ ). Bovine lactoferrin (bLF), an iron and heparin-binding glycoprotein secreted into various biological fluids has been implicated in innate immunity and has anti-inflammatory and anti-tumor functions. These findings suggest that bFGF; VEGF-C and PDGF-C have roles in the pathogenesis of OPA. The bLF may activate macrophages and plasma cells in these lesions, but limited expression of bLF by neoplastic cells may be a consequence of defective or impaired function of this molecule (Sozmen and Beytut, 2012).

JSRV appears to be unique among retroviruses in inducing transformation of the differentiated epithelial cells of the lungs (Rosenberg *et al.*, 1997). Moreover, the only sites where JSRV is highly expressed *in vivo* are the transformed epithelial cells of the lung (Palmarini *et al.*, 1996), although viral DNA and RNA are detected *in vivo* in various lymphoid organs (Fig.1). In lymphoid cells, JSRV can be detected in naturally infected sheep before the onset of clinical disease and even before the development of discernible neoplastic lesions (Gonzalez *et al.*, 2001).



**Figure 1:** Immunohistochemistry of a lung section of a sheep with ovine pulmonary adenocarcinoma

**Brown staining** represents positive reaction of a rabbit antiserum toward the major capsid protein of jaagsiekte sheep retrovirus.. Original magnification  $\times 250$ . (Source: Fan, 1994).

The envelope gene and the long terminal repeat (LTR) are the major determinants of retroviral tropism. The envelope gene encodes the viral glycoprotein that specifically interacts with the cellular receptor(s) necessary for viral entry. Retroviruses are able to infect only cells expressing their specific receptor. On the other hand, the LTR contains the viral promoter and enhancer elements that specifically interact with the cellular transcriptional machinery. After viral entry and integration, the LTR drives viral expression most efficiently in those cells expressing transcription factors that interact with the viral enhancer elements (Fan, 1994).

#### 5. CLINICAL SIGN AND PATHOLOGY

There is no reliable laboratory method for the ante-mortem diagnosis of OPA in individual animals at this time, therefore flock history, clinical signs and post-mortem lesions are the primary method for the diagnosis of the disease. As OPA has a long incubation period, clinical disease is encountered most commonly in sheep over 2 years of age, with a peak occurrence at the age of 3–4 years. In exceptional cases, the disease occurs in animals as young as 2–3 months of age. The cardinal signs are those of a progressive respiratory embarrassment, particularly after exercise; the severity of the signs reflects the extent of *tumor* development in the lungs. Death is often precipitated by a superimposed bacterial pneumonia, particularly that due to *Mannheimia* (formerly *Pasteurella multocida*) *haemolytica*. In clinically affected animals, a peripheral lymphopenia characterized by a reduction in CD4<sup>+</sup> T lymphocytes and a corresponding neutrophilia may assist clinical diagnosis, but the changes are not pathognomonic and are not detected during early experimental infection (Summers *et al.*, 2002).

##### 5.1. Clinical sign

Ovine pulmonary adenocarcinoma should be suspected in sheep with chronic respiratory signs, particularly in 2 - to 4-year-old animals with a frothy mucoid discharge from the nostrils. The “wheelbarrow test” – raising the hind legs to lower the head of the animal – can be used to check for excess fluid in the lungs. This test does not detect all sheep with tumors. Early cases are difficult to distinguish from other respiratory diseases (summers, *et al.*, 2005).

Clinical signs occur only in animals that have developed tumors. The signs may include progressive emaciation, weight loss and respiratory compromise, particularly after exercise. Affected sheep often lag behind the flock. There is usually a thin mucus discharge from the nostrils, and if the head is lowered, a copious frothy ex-

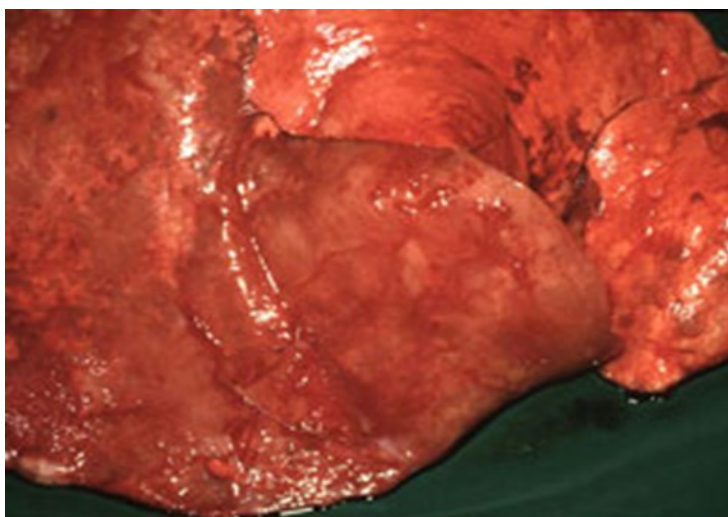
update may pour from the nares. Moist rales may be heard on auscultation, but coughing is not usually prominent. The clinical signs are slowly progressive, ending in severe dyspnea. Death usually occurs in days to a few months, often from secondary bacterial pneumonia (De Las Heras, *et al.*, 2005).

### 5.2. Laboratory tests

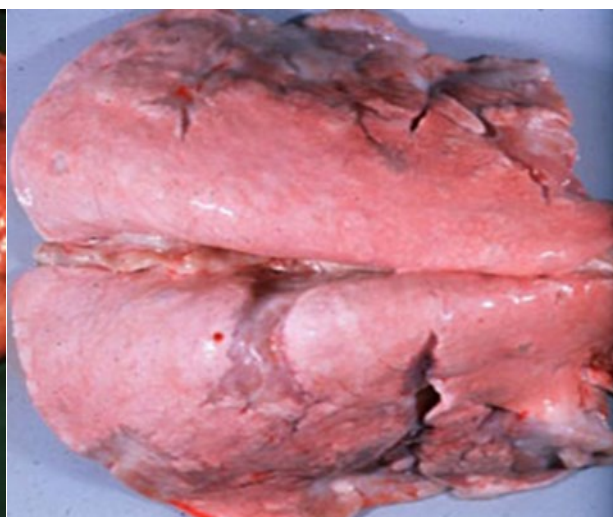Jaagsiekte sheep retrovirus cannot be recovered in culture. No reliable ante mortem test exists, and in living animals, ovine pulmonary adenocarcinoma is often diagnosed using clinical signs combined with flock history. At necropsy, the diagnosis is based on gross lesions, histopathology, and testing to detect viral antigens or RNA. Immunohistochemistry, immunoblotting and polymerase chain reaction (PCR) assays can detect JSRV antigens or RNA in tumors and lung fluids (Summers *et al.*, 2002).

### 5.3. Post-Mortem Lesions

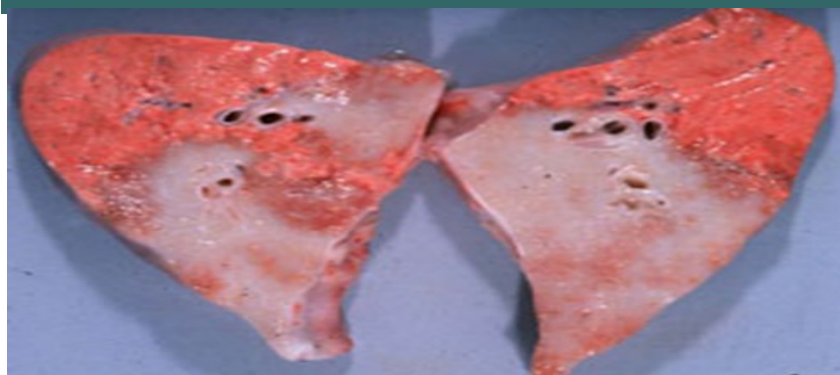The lungs are usually enlarged in animals with typical OPA, and in advanced cases, they do not collapse upon opening the chest cavity. Frothy fluid may be seen in the trachea and bronchi. Tumors are found in the lungs, particularly in the apical, cardiac and ventral portions of the diaphragmatic lobes. They vary from small nodules to solid masses, and are sharply demarcated, firm, and gray or pinkish-gray (Fig.2). On cut surface, the tumors are glistening and granular; a frothy fluid may be expressed. Secondary pneumonia and fibrinous pleuritis are often found. Tumor metastasis usually occurs only to nearby lymph nodes. Atypical cases that have solitary or aggregated hard white nodules with a dry cut surface can also be seen. These tumors are usually clearly demarcated, and excess fluid in the lungs is not a prominent feature (Palmarini *et al.*, 1999).



Sheep, lung. The lungs fail to deflate and are mottled with coalescing to diffuse proliferative areas (pale pink) with red areas of atelectasis



Sheep, lung. The lungs fail to deflate and the ventral edges of the lungs contain multiple white proliferative and fibrotic coalescing nodules



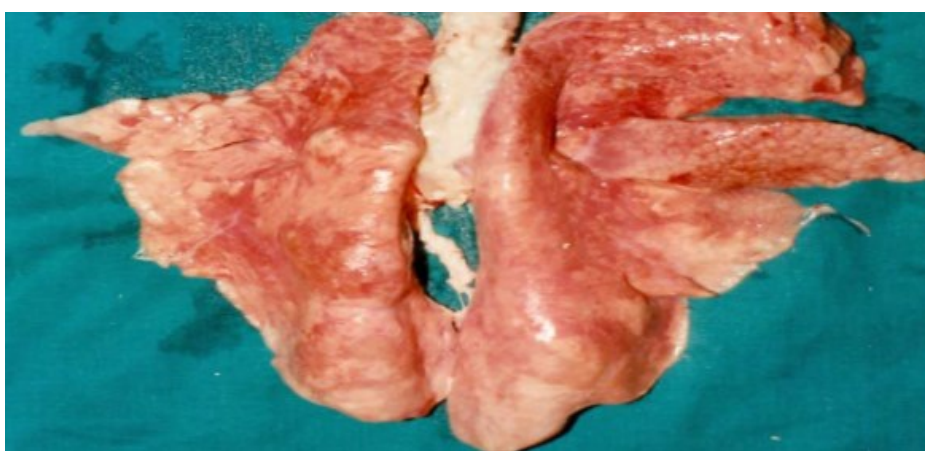
Sheep, lung. The cut surface of the lung has large, firm, gray coalescing proliferative and fibrotic masses that are sharply demarcated

**Figure 2. Gross features of sheep lungs with Adenocarcinoma:** (Source: Dr. C. Clarke, University of Edinburgh, Noah's Arkive)

#### 5.4. Gross changes

OPA lesions are in most cases confined to the lungs, although intra- and extrathoracic metastasis to lymph nodes and other tissues can occur. In typical cases, affected lungs are considerably enlarged and heavier than normal due to extensive nodular and coalescing firm grey lesions affecting much of the pulmonary tissue. Usually lesions are present in both lungs, although the extent on either side does vary. *Tumors* are solid, grey or light purple with a shiny translucent sheen and often separated from the adjacent normal lung by a narrow emphysematous zone (Fig.3). The presence of frothy white fluid in the respiratory passages is a prominent feature and is obvious even in lesions as small as a few millimeters. In advanced cases, this fluid flows out of the trachea when it is cut or pendant. Samples should be taken at necropsy for histopathology, immunohistochemistry or PCR for JSRV (OIE, 2008).

Pleurisy may be evident over the surface of the *tumor* and often abscesses are present in the adenomatous tissue. In atypical OPA, *tumors* comprise solitary or aggregated hard white nodules that have a dry cut surface and show clear demarcation from surrounding tissues. The presence of excess fluid is not a prominent feature. Adult sheep, which on post-mortem examination appear to have died from acute pasteurellosis, should have their lungs examined carefully, as lesions of OPA may be masked by coexisting bronchopneumonia, verminous pneumonia, chronic progressive pneumonia (maedi-visna) or combinations of these. Samples should be taken at necropsy for histopathology (Gonzalez *et al.*, 2008).



**Figure 3:** Pulmonary adenomatosis, dorsal of goat lung (enlarged, light grey, edematous) affected by classical form of diaphragmatic, Middle and apical lobes show grayish-white nodules 50x. (Source: Sayyari, and Mohamadian, 2012).

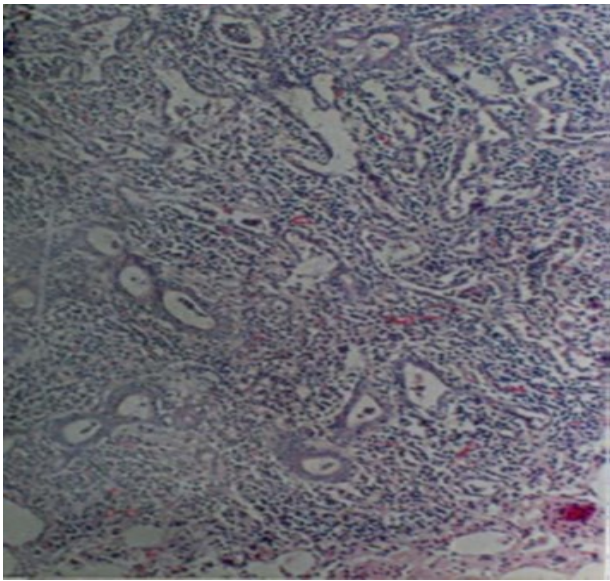
#### 5.5. Microscopic changes

Histologically, the lesions are characterised by proliferation of mainly type II pneumocytes, a secretory epithelial cell in the pulmonary alveoli. Nonciliated (Clara) and epithelial cells of the terminal bronchioli may be involved. The cuboidal or columnar *tumor* cells replace the normal thin alveolar cells and sometimes form papilliform growths that project into the alveoli. Intra-bronchiolar proliferation may be present. In advanced cases, extensive fibrosis may develop and, occasionally, nodules of loose connective tissue in a mucopolysaccharide substance may be present. A prominent feature is the accumulation of large numbers of alveolar macrophages in the alveoli adjacent to the neoplastic lesions (Summers *et al.*, 2005).

Lungs had few multifocal consolidated slightly elevated gray to white masses ranging from 0.5 to 3 cm in diameter. Histopathologically, these masses appeared as well-differentiated acinar adenocarcinoma with little evidence of anaplasia. JSRV protein was detected in all tumor epithelial cells, histologically normal alveolar type II cells, and few bronchiolar epithelial cells, alveolar macrophages, lymphocytes, and plasma cells (Samah and Sameh, 2011).

Where maedi-visna is concurrent, perivascular, peribronchiolar and interstitial lymphoid infiltrates may be prominent. The histological appearance of atypical OPA is essentially the same as classical OPA, but with an exaggerated inflammatory response (mostly lymphocytes and plasma cells) and fibrosis (De Las Heras *et al.*, 2003).

It is apparent that early tumor lesion develops close to the bronchioles. In this area both the epithelial lining of the bronchioli and the alveolar septa seem to be affected simultaneously. In the present study, the inflammatory cells were monocyte macrophage, lymphocyte, and polymorphonuclear leukocytes. The prominent reaction found in the affected lungs was the hyperplasia of the peribronchiolar lymphatic tissue aggregates (Fig.4). Because of the lymphatic aggregation around bronchiole, the size of bronchi had decreased and, due to the hyperplasia induced pressure, the alveoli around bronchi had disappeared. However, an interesting finding was the hyperplasia of smooth muscle cells in the interstitial tissues (Sayyari and Mohamadian, 2012).



**Figure 4:** Metaplasia of epithelial cell to columnar, peribronchiolar lymphocytic tissue associated with thickened alveolar septa, (H&E, ×50. (Source: Sayyaria and Mohamadian, 2012).

## 6. CONTROL AND PREVENTION

Ovine pulmonary adenocarcinoma is usually introduced into a flock in an infected sheep, often one that is sub-clinically infected. Because there is no diagnostic test to detect these animals, preventing entry is difficult. Herd replacements should be bought only from flocks with no history of ovine pulmonary adenomatosis; however, this does not ensure that the animals are free of jaagsiekte sheep retrovirus, as the incubation period is long. There is no effective treatment for animals with lung tumors, and no known method to prevent the infection from progressing to this stage. No vaccine is available for OPA (Radiostitis *et al.*, 2007).

Removing affected sheep and the offspring of infected ewes may reduce losses, but it cannot eradicate the disease from a flock. Embryo transfer can be used to save the genetic potential from flocks that are euthanized. A recent study suggests that ovine pulmonary adenomatosis may also be significantly reduced or eradicated by removing lambs at birth and hand-rearing them with colostrums substitutes or cow colostrums, followed by milk replacer (Rosenberg and Jolicoeur, 1997).

Good disinfection and general hygiene should be used when handling the lambs, and they should be placed in an uncontaminated environment. Retroviruses are fragile in the environment, and they are susceptible to most common disinfectants. Ovine pulmonary adenocarcinoma was eradicated from Iceland by slaughtering all sheep in affected areas (Sharp and Demartini, 2003).

## 7. CONCLUSION AND RECOMMENDATIONS

OPA is caused by infection from exogenous beta *retro virus* in the family *retroviridae* which has an oncogenic protein that develops lung tumor. This tumor causes respiratory distress to the animal that results in huge economic loss worldwide. The virus is transmitted by droplets from respiratory fluid, milk, and colostrum; as a result the agent has a high chance of contaminating the environment from excess respiratory discharge. The virus has a long incubation period that varies according to the age of the host. Lack of antibody development against the virus limits the use of serological tests and vaccine production; due to this the diagnostic option becomes minimal. Other than this, the virus can't grow in any laboratory animal except sheep and goat. Unlike ante-mortem diagnosis, post-mortem diagnosis has a significant lesion in the lung like tumor growth and accumulation of fluid in the airways. It has a wide range of distribution in the world. Sheep and goat importing countries from infested areas are largely at risk. Since the virus has a wide range of transmission, it takes little time to infect the whole flock. Based on the above conclusion, the following recommendations are forwarded:

- ◆ Since the disease is transmitted from infected sheep; herd replacement from infected areas should be banned.
- ◆ Environmental hygiene should be maintained from discharges and any virus-reserving matter.
- ◆ Neonates should grow by feeding milk replacement and colostrum from cow rather than sucking their dam to prevent transmission through milk.
- ◆ The affected and non-affected flocks should be stamped out to eradicate the diseases from the area.
- ◆ Mechanism of tumor production, vaccine development, public health importance and nature of tumor can be researched for the future.

## REFERENCES

1. Bai, J., Zhu, R.Y., Stedman, K., Cousens C., Carlson, J.O., Sharp, J.M. and De Martini, J.C. (1996): Unique Long Terminal Repeat U3 Sequencing Exogenous Jaagsiekte Sheep Retroviruses Associated with Ovine Pulmonary Carcinoma from endogenous loci in the Sheep Genome. *J. Virol.*, **70**:3159–3168.
2. Caporale, M., Centorame, P., Giovannini, A., Sacchini, F., Di Ventura, M., De Las Heras, M. and Palmarini, M. (2005): Infection of lung epithelial cells and induction of pulmonary adenocarcinoma is not the most common outcome of naturally occurring JSRV infection during the commercial lifespan of Sheep. *Virology*, **338**: 144–153.
3. CFSPH (2009): Ovine pulmonary adeno carcinoma, Pp. 1-4
4. Dawson, M., Venables, C. and Jenkins, C.E. (1985): Experimental infection of a natural case of Sheep Pulmonary Adenomatosis with Maedi-Visna Virus. *Vet. Rec*, **116**:588–589.
5. De Las Heras, M., Gonzalez, L.G. & Sharp, J.M. (2003): Pathology of Ovine Pulmonary Adenocarcinoma. *Curr. Top. Microbiol. Immunol*, **275**: 25–54.
6. De Las Heras, M., Ortín, A., Salvatori, D., Pérez De Villareal, M., Cousens, C., Ferrer, L.M., García De Jalón, J.A., Gonzalez, L. and Sharp, J.M. (2005): a PCR Technique for the detection of Jaagsiekte retrovirus in the blood suitable for the Screening of Virus infection in Sheep Flocks. *Res. Vet. Sci*, **79**: 259–264.
7. De Las Heras, M.; Barsky, SH., Hasleton, P., Wagner, M., Larson, E., Egan, J., Ortin, A., Gimenez-Mas, JA., Palmarini, M. and Sharp, JM. (2000): Evidence for a protein related immunologically to the jaagsiekte Sheep retrovirus in some human lung tumours. *Eur Respir J.*, **16**: 330-332.
8. Demartini, J.C., Bishop, J.V., Allen, T.E., Jassim, F.A., Sharp, J.M., De Las Heras, M., Voelker, D.R. and Carlson, J.O. (2001): Jaagsiekte Sheep Retrovirus proviral clone JSRV JS7, derived from the JS7 lung tumor cell line, induces Ovine Pulmonary Carcinoma and is integrated into the surfactant protein a Gene. *J. Virol.*, **75**: 4239–4246.
9. Fan, H. (1994): Retroviruses and Their Role in Cancer. In: Levy Ja, Editor. *The Retroviridae*. New York: Plenum Press, **3**: 313–316.
10. Gonzalez, L., Garcia-Goti, M., Cousens, C., Dewar, P., Cortabarría, N., Extramiana, B., Ortin, A., De Las Heras, M. and Sharp, J.M. (2001): Jaagsiekte Sheep Retrovirus can be detected in the peripheral blood during the preclinical period of Sheep Pulmonary Adenomatosis. *J. Gen. Virol.*, **82**: 1355–1358.
11. Gonzalez, L., Juste, R.A., Cuervo, L.A., Idigoras, I. and Saez De Ocariz, C. (2008): Pathological and Epidemiological aspects of the coexistence of Maedi-Visna and Sheep Pulmonary Adenomatosis. *Res. Vet. Sci.*, **54**: 140–146.
12. Griffiths and J. Comps. (2010): Pathology and Pathogenesis of Ovine Pulmonary Adenocarcinoma, **142**: 260-283.
13. Hecht, S.J., Carlson, J.O. and De Martini, J.C. (1994): analysis of a Type D Retroviral capsid gene expressed in Ovine Pulmonary Carcinoma and present in both affected and unaffected Sheep Genomes. *Virology*, **202**: 480–484.
14. Holland, M.J., Palmarini M., Garcia-Goti, M., Gonzalez, L., De Las Heras, M. and Sharp, J.M. (1999): Jaagsiekte Retrovirus establishes a pantropic infection of lymphoid cells of Sheep with naturally and experimentally acquired Pulmonary Adenomatosis. *J. Virol.*, **73**: 4004–4008.
15. Jassim, F.A. (1988): Identification and characterisation of transformed cells in Jaagsiekte, a contagious lung *Tumor* of Sheep. PhD Thesis. University Of Edinburg.
16. Kahn, Cm. and Line, S. (2006): Editors, *The Merck Veterinary Manual*. White house Station, NJ: Merck and Co. Pulmonary Adenomatosis, Pp.123-243.
17. OIE (2008): Ovine pulmonary adenocarcinoma; Terrestrial Manual. Adenomatosis, **12**: 1031-1035.
18. Ortin, A., Minguíjon, E., Dewar, P., Garcia, M., Ferrer, L.M., Palmarini, M., Gonzalez, L., Sharp, J.M. and De Las Heras, M. (1997): Lack of A specific immune response against a recombinant capsid protein of Jaagsiekte Sheep retrovirus in Sheep and Goats naturally affected by enzootic nasal *Tumor* Or Sheep Pulmonary Adenomatosis. *Vet. Immunopathol.*, **61**: 239–237.
19. Palmarini, M., Sharp, J.M., De Las Heras, M. and Fan, H.Y. (1999): Jaagsiekte Sheep Retrovirus is necessary and sufficient to induce a contagious lung cancer in Sheep. *J. Virol.*, **73**: 6964–6972.
20. Palmarini, M., Cousens, C., Dalziel, R.G., Bai, J., Stedman, K., Demartini, J.C. and Sharp, J.M. (1996): The exogenous form of Jaagsiekte Retrovirus (JSRV) is specifically associated with a contagious lung cancer of Sheep. *J. Virol.*, **70**:1618–1623.



21. Palmarinin, M., Mura, M. and Spencer, T. (2004): endogenous Betaretroviruses of Sheep. Teaching new lessons in retroviral interference and adaptation. *J. Gen. Virol.*, **85**: 1–13.
22. Radiostits, M. O; Guy,C.C; Hinchcliff, W. K and Constable, D. P. (2007): *Veterinary Medicine a Text-book of the disease of Cattle, Sheep, Pigs , Goats And Hors.*10<sup>th</sup> Edition .London Elsevlersaunder,Pp, 1366-1368.
23. Rosenberg, N and Jolicoeur, P. (1997): *Retroviral Pathogenesis. Retroviruses.* Cold Spring Harbor: Cold Spring Harbor Laboratory Press, Pp. 475–485.
24. Salvatori, D. (2005): *Studies on the Pathogenesis and Epidemiology of Ovine Pulmonary Adenomatosis (OPA).* PhD Thesis, University of Edinburgh, Scotland, UK. Pp.11-15.
25. Salvatori, D., Cousens, C., Dewar, P., Ortin, A., Gonzalez, L., De Las Heras, M., Dalziel, R.G. and Sharp, J.M. (2004): effect of age at inoculation on the development of Ovine Pulmonary Adenocarcinoma. *J. Gen. Viri.*, 467-634.
26. Samah, S. O. and Sameh, A. Y. (2011): *Immunohistochemical and Histopathological Findings of Ovine Pulmonary Adenocarcinoma (Jaagsiekte) In Egyptian Sheep.* *Lib.Bioinfo.Pl/Paper:21626063.*
27. Sanna, M.P., Sanna, E., De Las Heras, M., Leoni, A., Nieddu, Am., Pirino, S., Sharp, Jm. and Palmarini, M. (2001): association of Jaagsiekte Sheep Retrovirus with Pulmonary Carcinoma in Sardinian Moufflon (*Ovis Musimon*). *J Comp Pathol.*, **85**: 3319–3324.
28. Sayyari, M. and Mohamadian, B. (2012): Histopathological study of naturally occurring ovine Pulmonary Adenocarcinoma in native Goat in Khuzestan, Iran, **13**: Pp. 337.
29. Sharp, J.M. and Demartini, J.C. (2003): Natural history of JSRV in Sheep. *Curr. Top. Microbiol. Immunol.*, **275**: 55–79.
30. Sharp, J.M., Herring, A.J., Angus, K.W., Scott, F.M.M. and Jassim, F.A. (1985): isolation and *In Vitro* Propagation of a Retrovirus from Sheep Pulmonary Adenomatosis. *In Slow Virus Diseases in Sheep, Goats and Cattle*, Pp.345–348.
31. Sozmen, M. and E. Beytut (2012): an investigation of growth factors and lactoferrin in naturally occurring ovine Pulmonary Adenomatosis. *Lib.Bioinfo.Pl/Paper:21626063*
32. Summers, C., Neill, W., Dewar, P., Gonzalez, L., Van Der Molen, R., Norval, M. and Sharp, J.M. (2002): Systemic Immune Responses following infection with Jaagsiekte Sheep Retrovirus and in the Terminal stages of Ovine Pulmonary Adenocarcinoma. *J. Gen. Virol.*, **83**:1753–1757.
33. Summers, C., Norval, M., De Las Heras, M., Gonzalez, L., Sharp, J.M. and Woods G.M. (2005): an influx of Macrophages is the predominant local immune response in Ovine Pulmonary Adenocarcinoma. *Vet. Immunol. Immunopathol.*, **106**: 285–294.
34. Voigt, K., Brüggmann, M., Huber, K., Dewar, P., Cousens, C., Hall, M., Sharp, J.M. and Ganter, M. (2007): PCR Examination of bronchoalveolar lavage Samples is a useful tool in preclinical diagnosis of Ovine Pulmonary Adenocarcinoma (Jaagsiekte). *Res. Vet. Sci.*, **12**: 47-63.
35. York, D.F., Vigne, R., Verwoerd, D.W. and Querat, G. (1992): Nucleotide Sequence of the Jaagsiekte Retrovirus, an exogenous and endogenous Type D and B Retrovirus of Sheep and Goats. *J. Virol.*, **66**: 4930–4939.

## Contact Us:

### SIFT DESK

Deerpark Dr, #75, Fullerton,CA,92831,United States.

E-mail:

[helpdesk@siftdesk.org](mailto:helpdesk@siftdesk.org)

Visit us on the web at: [www.siftdesk.org](http://www.siftdesk.org)