

# A comparative morphological study of the spinous processes of the sixth and seventh cervical vertebrae in extinct and extant species of *Equus*

Sharon May-Davis\*, Robert Hunter, and Wendy Y. Brown

University of New England, Canine and Equine Research Group, Armidale, New South Wales, Australia  
maydavis@bigpond.com; anthropol@outlook.com; wbrown@une.edu.au

**Abstract:** The lateral profile of the 6th and 7th cervical spinous processes (CSPs) were examined in four extant species of *Equus* (n=33); *E. caballus* (n=26), *E. przewalskii* (n=3), *E. quagga boehmi* (n=1), *E. asinus* (n=3) and compared to pre-domesticated *Equus* specimens (n=66) representing three known species; *E. occidentalis* (n=56), *E. mosbachensis* (n=2), *E. curvedins/insulatis* (n=1) and unknown *Equus* species (n=7) from five museums. Six common morphological profiles were revealed: cuneate, curvate, falcate, rudimentary, scalenate, and truncate. For the 6th CSP, the distribution of these morphologies amongst extant *Equus* is: cuneate, only *E. asinus*; curvate, *E. caballus* and *E. przewalskii* always in combination with *ligamentum lamina nuchae* (*lig. lamina nuchae*) attachments from the 2nd through to 7th CSP inclusive; falcate, *E. caballus* and *E. przewalskii* always in combination with *lig. lamina nuchae* attachments from the 2nd through to 7th CSP inclusive; rudimentary, *E. caballus* always associated with *lig. lamina nuchae* attachments from the 2nd through to 5th CSP inclusive; scalenate, *E. caballus* in association with *lig. lamina nuchae* attachments from the 2nd through to 5th (n=11) or 7th (n=4) CSP inclusive; truncate, not present. The 6th CSP in museum specimens of *Equus* exhibits one of four profiles: cuneate (n=10), curvate (n=14), scalenate (n=11) and truncate (n=4). For the 7th CSP, the distribution of these morphologies amongst extant *Equus* is: curvate, *E. caballus* mostly associated with *lig. lamina nuchae* attachments from the 2nd through to 5th CSP inclusive, falcate, *E. caballus* mostly associated with *lig. lamina nuchae* attachments from the 2nd through to 7th CSP inclusive, scalenate, *E. caballus* associated with *lig. lamina nuchae* attachments from the 2nd through to 5th CSP inclusive. Only Rancho La Brea and Tar Pits Museum provided samples suitable for examination of the 7th CSP. These exhibited four profiles: curvate (n=7), falcate (n=11), scalenate (n=2), and truncate (n=7). These findings suggest that the lateral profile of the 6th CSP is of potential use in identification of species; attachments of the *lig. lamina nuchae* alter the morphology of the 6th and 7th CSP; and that attachments of the *lig. lamina nuchae* on the 2nd to 7th CSP were likely present in species of *Equus* prior to domestication.

## INTRODUCTION

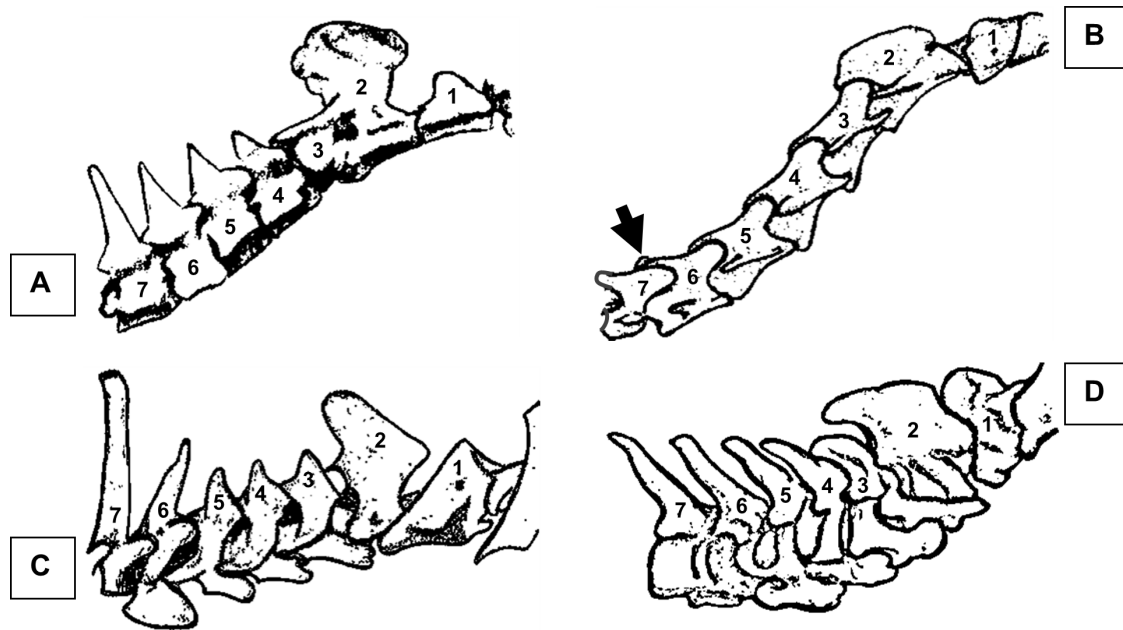
The number of cervical vertebrae in mammals became fixed more than 200 million years ago (mya); the canonical number of seven cervicals is well established by palaeontological evidence (Buchholtz et al. 2012; Arnold 2020). The mammalian cervical spine, considered as a morphologically static feature (Arnold et al. 2017), typically includes dorsally positioned spinous processes on some or all of the 2nd to 7th cervical vertebrae (Zsoldos and Licka 2015; Arnold 2020). The North American Eocene perissodactyl

*Hyracotherium* (Buchholtz et al. 2012; MacFadden 1992) bears blade-like spinous processes on the 4th to 7th cervical vertebrae (Wood et al. 2011) (Fig. 1A). This morphological trait is still retained in two of three extant perissodactyl families, namely Tapiridae and Rhinocerotidae (Fig. 1C, D). Members of the third family, Equidae (the hippomorphs) lack distinct spinous processes on the 3rd to 5th, with those on the 6th and 7th greatly reduced (Getty 1975) (Fig. 1B).

Cervical spinous processes (CSPs) provide important attachment sites for neck and back musculature, as well as ligamentous structures such as the *lig. lamina nuchae*

Published June 21, 2021

© 2021 by the authors; submitted April 13, 2021; revisions received June 9, 2020; accepted June 10, 2020. Handling editor: Robert Holmes. DOI 10.18435/vamp29373



**Figure 1.** Cervical spinous processes of perissodactyls; A, Eocene *Hyracotherium*; B, modern domestic horse - *Equus caballus* breed Thoroughbred (7th arrowed) – note the normal morphological presentation of the 7th spinous process and its position between the articulation of the 6th and 7th cervical vertebrae; C, Malayan tapir - *Tapirus indicus*; D, Sumatran rhinoceros - *Dicerorhinus sumatrensis*. (Sketches by 1st author).

(Getty 1975; Wood 2011; Zsoldos and Licka 2015; Arnold 2020). This ligament attaches to the CSPs from the 2nd to 7th in extant Tapiridae and according to early pre 1900s anatomic literature also in *E. caballus* in Equidae (Muir 1871; Wood et al. 2011; Singh 2018; May-Davis et al. 2018; Arnold 2020). A similar morphology has been reconstructed for the Eocene perissodactyl *Hyracotherium* (Wood et al. 2011). Eocene perissodactyls were browsers, and the morphology of the cervical vertebrae in *Hyracotherium* reflects the orientation and magnitude of forces applied to its cervical ‘S’ shaped spine (MacFadden 1992; Wood et al. 2011; Zsoldos and Licka 2015, Arnold 2020). This orientation of the spinous processes allows for greater dorsoventral flexion, an ideal characteristic for browsing (Wood et al. 2011). By the mid-Miocene it is believed that *Merychippus*, a hippomorph descendant of *Hyracotherium*, had evolved a primarily grazing habit (MacFadden, 1992) and consequently the forces acting upon the cervical column were significantly altered (Nussey et al. 2007; Zsoldos and Licka 2015). This is evidenced by the significant reduction in the spinous processes from those of *Hyracotherium* to *Merychippus* with only the 6th and 7th still presenting a raised apex/eminence in the latter (personal observation of museum specimens and replicas) (Fig. 2).

A reduction in *lig. lamina nuchae* attachments from the 6th and 7th CSP has been reported in 30 breeds of domestic *E. caballus*; however, this derived morphology does not extend to all breeds of *E. caballus* or other extant species of *Equus* (May-Davis and Kleine 2014, May-Davis et al.


2018, 2020b, c). In addition, where the attachments of the *lig. lamina nuchae* extend from the 2nd to 7th CSP in extant species of *Equus*, the lateral profiles of the 6th and 7th CSP differ from those in extant species of *Equus* where attachments of the ligament are restricted to the 2nd to 5th CSP (May-Davis et al. 2018; 2020a). Although the evolutionary development of the equine limb has been studied extensively, an equivalent treatment of the cervical spine is still lacking (Zsoldos and Licka 2015).

In concurrence with Zsoldos and Licka (2015), this study investigates the lateral morphological profile of the 6th and 7th CSPs in four extant species of *Equus*. After establishing the common profiles, we compare these species with museum specimens of pre-domesticated *Equus*. The aim is to: (i) identify potential species-specific traits to assist palaeontologists in the identification of museum specimens in *Equus* and (ii) investigate evidence for the presence or absence of attachments of the *lig. lamina nuchae* from the 2nd to 7th CSP in pre-domesticated *Equus*.

## METHODS

### Preparation of Extant Specimens *Equus caballus*, *Equus przewalskii*, *Equus quagga boehmi* and *Equus asinus*

**Ethical Statement:** No equids were euthanised for the purpose of this study and all observations were obtained postmortem.



**Figure 2.** Cervical vertebrae in two extinct equids noting the 6th and 7th spinous processes; A, Eocene *Hyracotherium*; B, Miocene *Merychippus*. (Photographs by 1st author).

**Anatomical Terminology:** The anatomical terms for this manuscript followed the terminology from *Nomina Anatomica Veterinaria* 6th edition (Gasse et al. 2017), except regarding *tuberculum dorsale*. Here the authors revert to anatomical terminology from Getty (1975) citing the equivalent skeletal structure as spinous process. Descriptive terminology of the spinous process notes the dorsal tip as 'eminence' when rounded, and 'apex' when pointed.

**Functional Anatomy:** The *lig. lamina nuchae* consists of a bilateral sheet of yellow elastin ligamentous fibres that arise from the spinous processes of the 2nd and 3rd thoracic vertebrae and the *ligamentum funiculus nuchae*, after which they traverse cranioventrally and insert on the CSPs from the 2nd to 7th cervicals in *E. przewalskii*, *E. quagga boehmi* and *E. asinus*. In modern (domestic) *E. caballus*, the *lig. lamina nuchae* primarily inserts from the 2nd to 5th CSPs, with rare variations extending to the 6th, and/or 7th CSP. Although reports of primitive and isolated breeds of *E. caballus* and close descendants of *Equus ferus ferus* often present the *lig. lamina nuchae* attachments from the 2nd to 7th CSPs (May-Davis et al. 2018, 2020b, c).

As the bilateral sheets of *lig. lamina nuchae* descend towards the CSPs, they form digitations prior to attachment; the only exception is *E. asinus* in which the *lig. lamina nuchae* remains an unbifurcated sheet (Sisson 1975; May-Davis and Kleine 2014; May-Davis et al. 2018, 2020a).

The function of the *lig. lamina nuchae* is to support and stabilize the cervical vertebrae while assisting locomotive gaits (Gellman and Bertram 2002; Dunbar et al. 2008).

In the four extant species, the 6th and 7th CSPs are dorsal projections on the raised, sagittal ridge on the dorsal surface of the vertebral lamina. They present with a cranial and caudal margin that is demarcated by an apex or eminence. The height and orientation of the CSPs are individually

variable in *Equus*, though Getty (1975) describes the 6th CSP in *E. caballus* as a rudimentary profile, while the 7th is raised. Cervical spinous processes function to provide attachment sites and anchorage for musculature and ligamentous structures to act on during locomotion, stance, and head relocation for the vestibular apparatus (Getty 1975; Sisson 1975a, b; Haussler 2016).

**Animal Details:** A total of 33 representative specimens of four species of equids were dissected and examined: *E. caballus* (n=26), *E. przewalskii* (n=3), *E. quagga boehmi* (n=1) and *E. asinus* (n=3). *Equus caballus* specimens are divided into two categories that are determined by the number of CSPs to which the *lig. lamina nuchae* attaches, either from the 2nd to 5th CSPs (n=17) or 2nd to 7th CSPs (n=9). The category 2nd to 5th comprises the following breeds: Crossbred (n=1); Dutch Konik (n=2); Exmoor (n=2); Quarter horse (n=2); Shetland (n=1); Thoroughbred (n=6); Warmblood (n=2); Welsh Mountain Pony (n=1). The category 2nd to 7th comprises isolated breeds: Australian Stock Horse (n=2); Bosnian Mountain Horse (n=1); Dutch Konik (n=2); Waler (n=1); Yonaguni pony (n=3). It should be noted that *E. przewalskii*, *E. quagga boehmi* and *E. asinus* present with *lig. lamina nuchae* attachments from the 2nd to 7th CSPs. The ages range from 16mths – 23 years and comprised of 16 males and 18 females.

**Source:** *Equus caballus* were obtained from either an abattoir, or postmortem following death by natural causes or veterinary recommendation for euthanasia in Australia, Japan, Slovenia, Netherlands, and United Kingdom. *Equus asinus* was obtained from an abattoir in Australia; *E. przewalskii* from Hortobagy Nature Reserve in Hungary and *E. quagga boehmi* from Emmen Zoo in the Netherlands.



**Dissections:** Protocols established by May-Davis et al. (2018) resect the neck musculature to reveal the attachments of the *lig. lamina nuchae* to the CSP. Further resection of the *lig. lamina nuchae* reveals the profiles of the 6th and 7th CSPs.

**Maceration, Degreasing and Photography:** Twenty-four specimens required maceration postmortem following the protocols established by May-Davis et al. (2020a), observations of the remaining nine specimens were *in situ*. The photographic view is left lateral for continuity and individual specimens follow those protocols established by May-Davis et al. (2020a).

### Fossil Specimens

**Museums:** Five museums with suitable specimens provided access for the study. Only those 6th and 7th cervical specimens with complete CSP or morphology sufficiently intact were examined. In total 66 specimens (6th n=39; 7th n=27) are included. Specimens of the 6th cervical vertebrae were obtained from: Natural History Museum Berlin (unidentified *Equus* species, n=6); Rancho La Brea Tar Pits and Museum Los Angeles (*E. occidentalis*, n=29); Monrepos Archeological Research Center and Museum for Human Behavioral Evolution Germany (*E. mosbachensis*, n=2); Natural History Museum Rotterdam (unidentified *Equus* species, n=1) and the Swedish Royal Museum and Natural History Stockholm (*E. curvedins/ insulatis*, n=1). Additionally, suitable specimens of the 7th cervical vertebra were examined at Rancho La Brea Tar Pits and Museum Los Angeles (*E. occidentalis* n=27).

**Photography:** In total, 66 specimens were photographed following the protocol established by May-Davis et al. (2020a), except specimens were handheld. Photographic images are in left lateral view only for continuity.

### Describing the Left Lateral Profile of the 6th and 7th Cervical Spinous Processes

This description of the lateral profiles of the 6th and 7th cervical spinous processes in four species of extant *Equus* and museum specimens of pre-domesticated *Equus*, uses the basic terminology applied by Meyer et al. (2015) in a

comparative study of thoracic vertebrae in hominids. The cited authors compared the laminar of the thoracic vertebra of *Australopithecus afarensis* (specimen AL 288-1 am) to that of *Papio* and noted a morphological similarity exemplified by a triangular shape, referring to it as the superior laminar trigon.

Here we follow similar protocols where the profiles of the spinous processes are characterised according to the shape bounded by four basic morphological features: baseline of the spinous process, cranial margin, eminence/apex and caudal margin (Fig. 3).

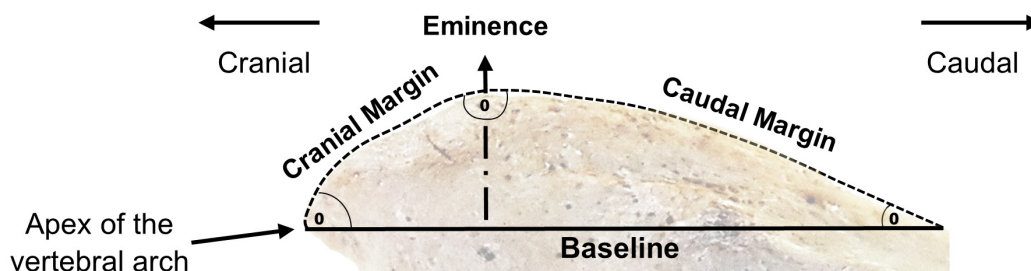
The baseline for each profile is determined with a straight line extending from the apex of the vertebral arch to where the caudal aspect of the dorsal spine diminishes and blends into either the sagittal ridge or the caudal border of the vertebra (whichever comes first). The cranial margin extends from the eminence/apex to the cranial aspect of the baseline. The caudal margin extends from the eminence/apex to the caudal aspect of the baseline.

The outline for each margin creates a shape, either convex, concave or straight. The combination of the four morphological features and their outlines (baseline, cranial and caudal margin, and eminence/apex) provides a shape that can be related to either a biological or botanical profile (Arnold, 2021; Pellow, Henwood and Carolin, 2010).

## RESULTS

### Spinous process morphology of the 6th and 7th cervical vertebrae

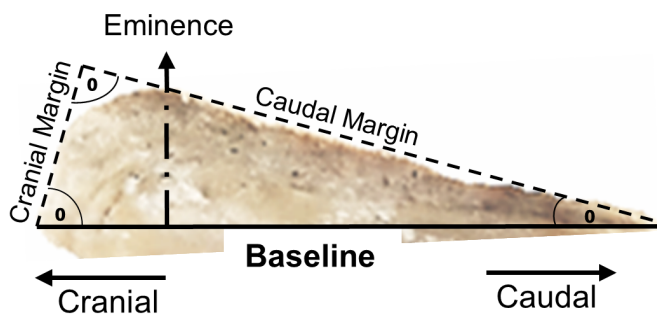
Six primary lateral profiles were identified as representative of the 6th and/or 7th CSP. Each profile was indicative of a botanical or biological shape: cuneate (wedge shaped), curvate (a curved form), falcate (sickle or hooked shaped), rudimentary (underdeveloped or no profile), scalenate (unequal sides), and truncate (cut off across the top) (Tab. 1). The specific profiles observed were dependent on the number of CSPs to which the *lig. lamina nuchae* attaches. Two distinct attachment patterns were



**Figure 3.** Cervical spinous process presenting four morphological features: baseline of the spinous process, cranial margin, eminence, and caudal margin.


**Table 1.** Summary of six primary profiles observed in the 6th, and/or 7th cervical spinous process of four extant species of *Equus* and museum specimens of extinct *Equus*.

**Cuneate**



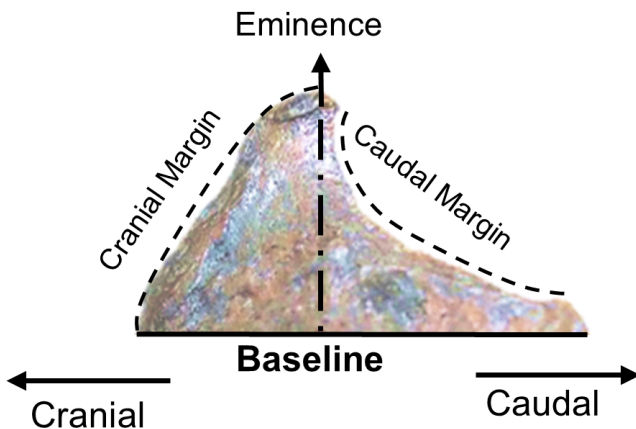
*Equus asinus* — C6 specimen 15 years old  
 Profile height: High to baseline  
 Cranial  $^{\circ}$ : >60  
 Eminence  $^{\circ}$ : Intersection of the lines associative to the cranial and caudal margins 90 degrees  
 Caudal  $^{\circ}$ : <30  
 Cranial Margin: Lesser than caudal in length  
 Eminence description: Rounded or apex  
 Caudal Margin: Greater than cranial in length

**Curvate**



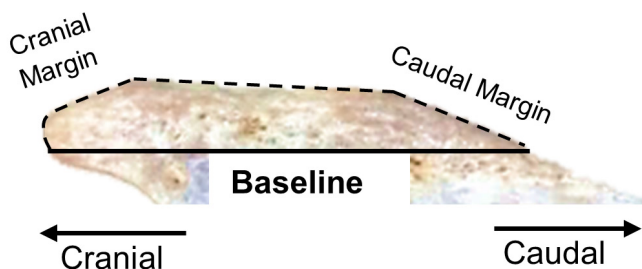
*Equus occidentalis* — C6 specimen Rancho La Brea and Tar Pits specimen No. 4 D2–99  
 Profile height: High to baseline  
 Cranial  $^{\circ}$ : N/A  
 Eminence  $^{\circ}$ : N/A  
 Caudal  $^{\circ}$ : N/A  
 Cranial Margin: Convex to the eminent line  
 Eminence description: Rounded  
 Caudal Margin: Convex to the eminent line

**Falcate**



*Equus occidentalis* — C7 specimen Rancho La Brea and Tar Pits Specimen No. 3 C3–4, 6.5  
 Profile height: High to baseline  
 Cranial  $^{\circ}$ : N/A  
 Eminence  $^{\circ}$ : N/A  
 Caudal  $^{\circ}$ : N/A  
 Eminence description: Rounded or apex  
 Cranial Margin: Predominantly convex to the eminent line  
 Caudal Margin: Predominantly concave to the eminent line

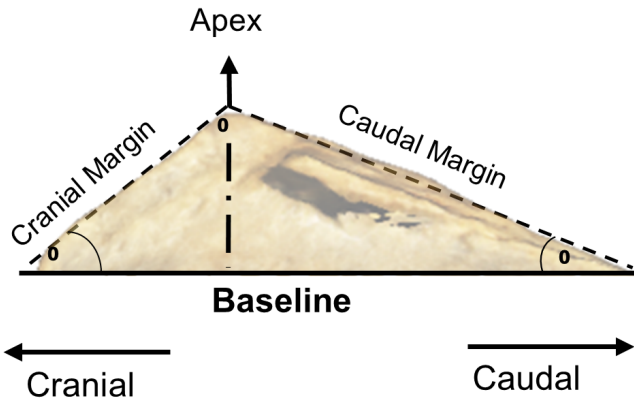
**Rudimentary**



*Equus caballus* — C6 specimen - Shetland pony >6 years old  
 Profile height: Low to baseline  
 Cranial  $^{\circ}$ : N/A  
 Eminence  $^{\circ}$ : N/A  
 Caudal  $^{\circ}$ : N/A  
 Cranial Margin: Lesser than caudal in length  
 Eminence description: Parallel to the baseline – long extended  
 Caudal Margin: Greater than cranial in length


Table 1 continued.

Scalenate



*Equus caballus* — C6 specimen Thoroughbred 22 years old  
 Profile height: High or low to baseline  
 Cranial  $^{\circ}$ :  $<60$   
 Eminence  $^{\circ}$ :  $>90$   
 Caudal  $^{\circ}$ :  $<30$   
 Cranial Margin: Lesser than caudal  
 Eminence description: Rounded or pointed  
 Caudal Margin: Greater than cranial

Truncate



*Equus occidentalis* — C6 specimen Rancho La Brea and Tar Pits  
 Specimen No. 2-3, F-4, 12  
 Profile height: Truncate  
 Cranial  $^{\circ}$ : Can be  $<90$   
 Eminence  $^{\circ}$ : N/A  
 Caudal  $^{\circ}$ : Can be  $>90$   
 Cranial Margin: Relatively straight and parallel to the caudal margin.  
 Eminence description: Relatively straight and can be parallel to the baseline or might present a cranial tilt.  
 Caudal Margin: Relatively straight and parallel to the cranial margin.

observed: the *lig. lamina nuchae* attachments from the 2nd to 5th CSPs, or from the 2nd to 7th CSPs (Tab. 2). Small variations in profile shape were observed yet they remained within the described guidelines (Tab. 1). Some profiles were further noted as high (where the CSP forms a distinct profile on the dorsal surface of the neural arch) and low (where the height of the profile is close vertically to the sagittal midline).

**The 6th cervical spinous process of four extant species and museum specimens of *Equus*:** *E. caballus* exhibits two distinct attachment patterns of the *lig. lamina nuchae*, 2nd to 5th, and 2nd to 7th. The 6th CSP of *E. caballus* (with *lig. lamina nuchae* attachments from the 2nd to 5th or 7th cervical vertebrae), *E. asinus* (Ea), *E. przewalskii* (Ep), *E. quagga boehmi* (Eqb) and museum specimens present all six primary profiles (Fig. 4).

***E. caballus* (2nd to 5th):** The 6th CSP present two low morphological profiles along the sagittal midline –

rudimentary 10/17 (59%) and scalenate 7/17 (41%). Incomplete non-functional *lig. lamina nuchae* were present in 10 specimens 10/17 (59%).

***E. caballus* (2nd to 7th):** The 6th CSP present two high morphological profiles along the sagittal midline – scalenate 4/10 (40%) and curvate 6/10 (60%). Both profiles are more robust in this category than in category 2nd to 5th, especially the eminence/apex of the scalenate profile, where the *lig. lamina nuchae* attachments occur at one location rather than those with curvate morphology.

***Equus asinus*:** The 6th CSP present one morphological profile that spans the entire length of the sagittal midline – cuneate 3/3 (100%). The *lig. lamina nuchae* (which attaches to the 2nd to 7th CSP) attaches to the cranial margin, eminence and caudal margin of the spinous process that spanned the entire length of the cervical vertebra from the cranial to caudal border. The cuneate profile appears morphologically robust.

**Table 2.** Summary of six primary profiles observed in the 6th, and/or 7th cervical spinous in association with two different *ligamentum lamina nuchae* attachment patterns (2nd to 5th and 2nd to 7th).

Breed	<i>Lig. lamina nuchae</i>	Cuneate	Curvate	Falcate	Rudimentary	Scalenate	Truncate
<b><i>Equus caballus</i> 6th Cervical Vertebra</b>							
Australian Stock Horse	2-7		*				
Australian Stock Horse	2-7		*				
Bosnian Mountain Horse	2-7		*				
Crossbred	2-5					*	
Dutch Konik	2-5				*		
Dutch Konik	2-5				*		
Dutch Konik	2-7		*				
Dutch Konik	2-7		*				
Exmoor	2-5					*	
Exmoor	2-5					*	
Quarter Horse	2-5					*	
Quarter Horse	2-5				*		
Shetland							
	2-5					*	
Thoroughbred	2-5					*	
Thoroughbred	2-5				*		
Thoroughbred	2-5				*		
Thoroughbred	2-5				*		
Thoroughbred	2-5				*		
Thoroughbred	2-5				*		
Waler	2-7					*	
Warmblood	2-5					*	
Warmblood	2-5				*		
Welsh Mountain Pony	2-5				*		
Yonaguni Pony	2-7					*	
Yonaguni Pony	2-7					*	
Yonaguni Pony	2-7					*	
<b>Extant <i>Equus</i> 6th Cervical Vertebra</b>							
<i>Equus asinus</i>	2-7	*					
<i>Equus asinus</i>	2-7	*					
<i>Equus asinus</i>	2-7	*					
<i>Equus przewalskii</i>	2-7		*				
<i>Equus przewalskii</i>	2-7			*			
<i>Equus przewalskii</i>	2-7			*			
<i>Equus quagga boehmi</i>	2-7			*			
<b><i>Equus caballus</i> 7th Cervical Vertebra</b>							
Australian Stock Horse	2-7		*				
Australian Stock Horse	2-7			*			
Bosnian Mountain Horse	2-7			*			
Crossbred	2-5			*			
Dutch Konik	2-5		*				
Dutch Konik	2-5		*				
Dutch Konik	2-7			*			
Dutch Konik	2-7			*			
Exmoor	2-5		*				
Exmoor	2-5		*				
Quarter Horse	2-5			*			
Quarter Horse	2-5			*			
Shetland	2-5					*	

Table 2 continued.

Breed	<i>Lig. lamina nuchae</i>	Cuneate	Curvate	Falcate	Rudimentary	Scalenate	Truncate
Thoroughbred	2-5					*	
Thoroughbred	2-5					*	
Thoroughbred	2-5		*				
Thoroughbred	2-5		*				
Thoroughbred	2-5		*				
Thoroughbred	2-5		*				
Waler	2-7			*			
Warmblood	2-5					*	
Warmblood	2-5		*				
Welsh Mountain Pony	2-5		*				
Yonaguni Pony	2-7			*			
Yonaguni Pony	2-7			*			
Yonaguni Pony	2-7			*			

**Extant *Equus* 7th Cervical Vertebra**

<i>Equus asinus</i>	2-7			*
<i>Equus asinus</i>	2-7			*
<i>Equus asinus</i>	2-7			*
<i>Equus przewalskii</i>	2-7			*
<i>Equus przewalskii</i>	2-7			*
<i>Equus przewalskii</i>	2-7			*
<i>Equus quagga boehmi</i>	2-7			*

Lig Int = Very large *Ligamenta interspinalia* attachment to the caudal margin of the C7 spinous process.

***Equus przewalskii*:** The 6th CSP present two morphological profiles along the sagittal midline – curvate 1/3 (33%) and falcate 2/3 (67%), with the curvate profile associated only with the youngest animal aged three. The attachments of the *lig. lamina nuchae* present similar morphology to that of *E. quagga boehmi*, with little variation and CSP profiles present with a very robust morphology.

***Equus quagga boehmi*:** The very robust 6th CSP presents one morphological profile along the sagittal midline – falcate 1/1 (100%), which corresponded directly with the cord-like attachment of the *lig. lamina nuchae* (which attaches from the 2nd to 7th CSP).

**Museum Specimens:** The 6th CSP present four morphological profiles along the sagittal midline – cuneate 10/39 (26%), curvate 14/39 (36%), scalenate (high) 11/39 (28%) and truncate 4/39 (10%). All CSP profiles present a robust morphology.

**The 7th cervical spinous process of four extant species and museum specimens of *Equus*:** The morphological profile of the 7th CSP of *E. caballus* (category 2nd to 5th and 2nd to 7th), *E. asinus*, *E. przewalskii*, *E. quagga boehmi* and museum specimens are shown in Figure 5.

***E. callabus* (2nd to 5th):** The 7th CSP present three low morphological profiles along the sagittal midline – curvate 10/17 (59%), falcate 2\*/17 (12%), and scalenate 5/17

(29%). The two examples of falcate profiles (\*) are reported in a 22-year-old Thoroughbred female and 15-year-old Quarter Horse male. Both present enlarged *ligamenta interspinalia* attaching to the entire length of the caudal margin from the eminence to the caudal border of the vertebra with a wide caudal orientation attaching to the entire length of the cranial margin of the 1st thoracic spinous process.

***E. callabus* (2nd to 7th):** The 7th CSP present two high morphological profiles along the sagittal midline – curvate 1/10 (10%), and falcate 1/9 (90%). The three profiles are more robust in this category than 2nd to 5th.

***Equus asinus*:** The lateral profile of the 7th CSP is, in all cases (3/3), falcate. In all cases, the profile is very robust. The attachments of the *lig. lamina nuchae* span the entire length of the cranial margin, eminence, and caudal margin of the spinous process.

***Equus przewalskii*:** In all cases (3/3), the 7th CSP exhibits a robust, falcate morphology. The *lig. lamina nuchae* attachments present similar morphology (with *lig. lamina nuchae* fibres combining to form cord like structures) with little variation between the specimens.

***Equus quagga boehmi*:** In the single available specimen, the 7th CSP exhibits a robust falcate morphology. The thick attachment of *lig. lamina nuchae* is the most extensive in the zebrine sample.



**Museum Specimens:** The 7th CSP present four morphological profiles – curvate 7/27 (26%), falcate 11/27 (41%), scalenate 2/27 (7%), and truncate 7/27 (26%). All forms present robust morphology, even the younger specimens.

## DISCUSSION

This study describes the morphological profile of the 6th and/or 7th CSP in four extant species of *Equus* and additionally examines museum specimens of pre-domesticated *Equus* from North America, South America, and Europe. We utilize the methodology of Meyer et al. (2015) to identify specific anatomic structures in order to describe six distinct profiles – cuneate, curvate, falcate, rudimentary, scalenate, and truncate.

In extant species, the 6th CSP exhibits a cuneate profile only in *E. asinus*, yet this profile is represented in 10 (26%) C6 museum specimens. This might indicate the specimens, such as *E. hermiones* and/or *E. hydruntinus*, are progenitors or close relations of *E. asinus*. Both species are known to have existed in the same geographical regions as pre-domesticated *Equus*, *E. hermiones* in North America and *E. hydruntinus* in Europe (Geigl and Grange 2012; Brown et al. 2015).

Curvate 6th CSP are present in two extant species – *E. caballus* (but only those individuals in which the *lig. lamina nuchae* attaches to the 2nd to 7th CSPs), and *E. przewalskii*, in which the *lig. lamina nuchae* also attaches to the

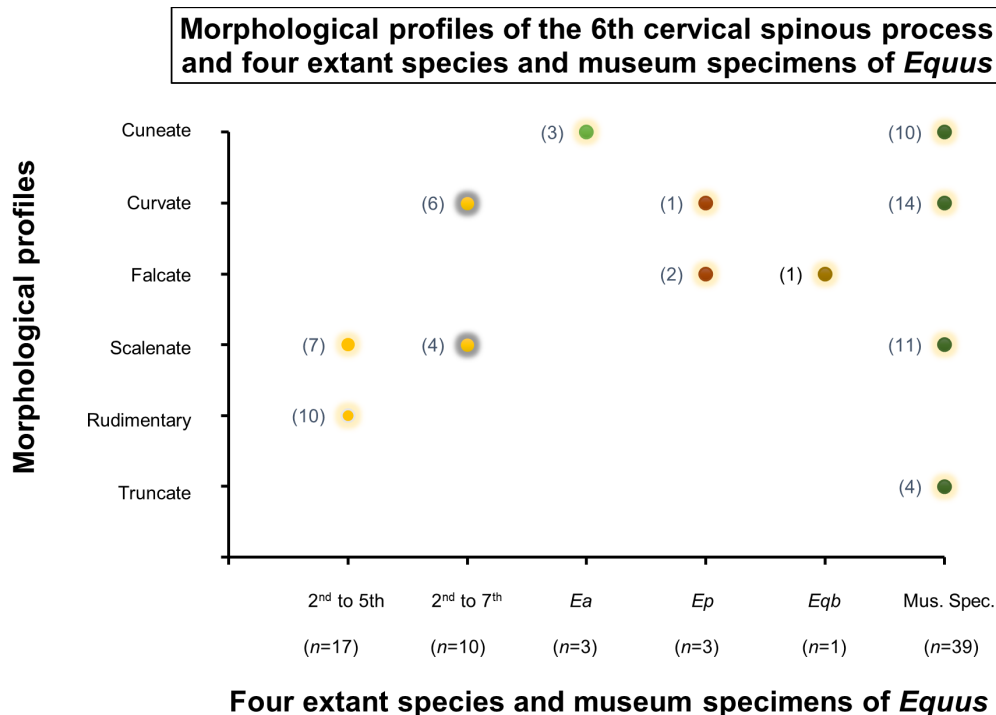
2nd to 7th CSPs. This morphological profile could therefore be a trait that coincides with the attachment of the *lig. lamina nuchae* to the 6th CSP and if so, is a likely indicator of a similar ligamentous attachment in museum specimens.

A falcate 6th CSP is present only in *E. przewalskii* and *E. quagga boehmi*; here the *lig. lamina nuchae* attachment to the 6th CSP in both species presents a robust morphology

A rudimentary 6th CSP is present in only one extant species – *E. caballus* in which the *lig. lamina nuchae* attaches to the 2nd to 5th CSP. This profile is likely a strong indicator of the absence of *lig. lamina nuchae* attachments to the 6th CSP, yet no museum specimens presented a rudimentary 6th CSP profile, which further implies these *lig. lamina nuchae* attachments were present in pre-domesticated *Equus*.

In *E. caballus*, a 6th CSP with a scalenate profile is associated with both *lig. lamina nuchae* attachment patterns from the 2nd to 5th and 2nd to 7th CSP. The latter category presents a profile with a more robust eminence/apex at the site of *lig. lamina nuchae* attachment. In museum specimens, the scalenate profile occurred in 11/39 (28%) of the specimens, and although robustness might correlate with the presence of *lig. lamina nuchae* attachments, it alone is not a reliable indicator, particularly in young animals. Further research into the relationship between the 6th CSP morphology and *lig. lamina nuchae* attachment is required.

Truncate 6th CSP are present only in museum specimens (4/39 or 10%); all appeared robust. The cuneate profile is not preserved in any of the fossil 7th CSP samples.



**Figure 4.** Morphological profile of the 6th cervical spinous processes in four extant species (n=33) and museum specimens (n=39) of *Equus*.

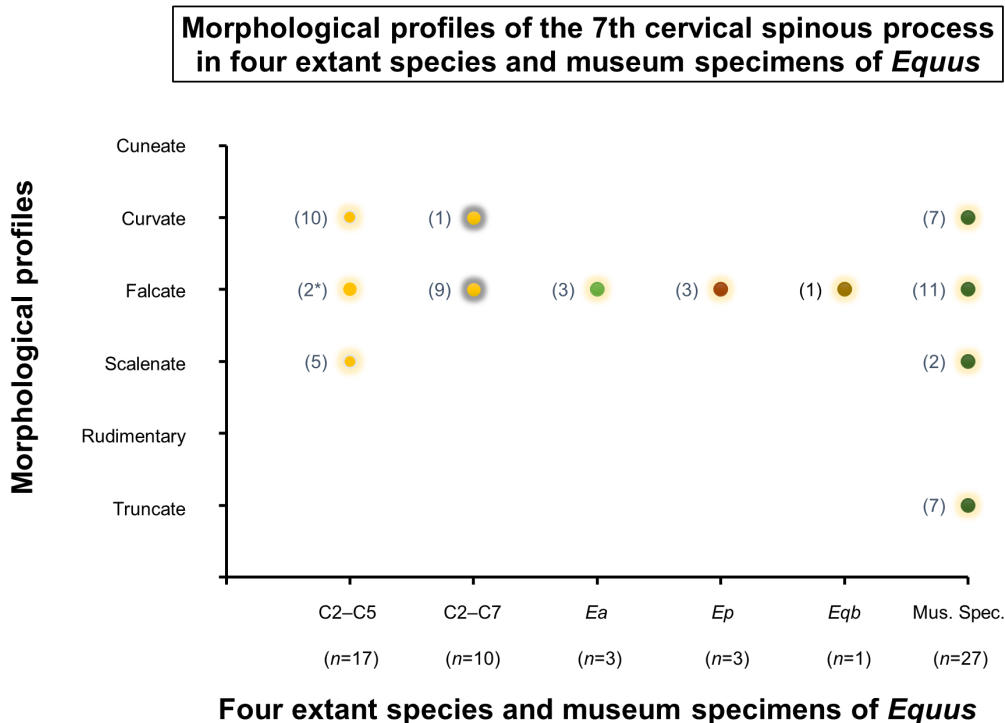
In *E. callabus*, a curvate 7th CSP is present in association with both ligament attachment patterns from the 2nd to 5th CSP (10/17) and 2nd to 7th CSP (1/9). This is a strong indication that this profile represents an absence of *lig. lamina nuchae* attachments. The curvate profile is exhibited by 7 of 27 (26%) 7th CSP from Rancho La Brea and Tarpits Museum. As a morphological profile, curvate is a strong indicator in extant species that a *lig. lamina nuchae* attachment to the 7th CSP is absent, indicating a potentially differing morphology in *lig. lamina nuchae* attachments in pre-domesticated *Equus*. However, this sample is geographically isolated and cannot be a definite indicator in all populations. Nevertheless, the robust condition of the 7th CSP of all museum specimens provides an opportunity in future to examine this material for potential entheses patterns and assess the influence of age on spine morphology.

The falcate profile is present in the 7th CSP of all extant species, categories, and museum specimens. However, the two falcate profiles (2\* in Fig. 5) present in *E. caballus* (both associated with ligament attaching from the 2nd to 5th CSP) are low and angled caudally with a straight cranial margin indicative of the scalenate profile. This might be attributed to forces applied from the large attachment of the *ligamenta interspinalia* along the caudal margin of the 7th CSP in these two specimens. In addition, these two falcate profiles were comparatively different in orientation to

those falcate presentations that were upright and robust in extant specimens with *lig. lamina nuchae* attachments from the 2nd to 7th CSP. A robust falcate profile is exhibited in 11/27 (41%) of the museum specimens. As evidenced in extant species, this profile is correlated to *lig. lamina nuchae* attachments the 2nd to 7th CSP inclusive, and therefore could be deemed an indicator of *lig. lamina nuchae* attachments in museum specimens as well.

A scalenate 7th CSP is present only in *E. caballus* with ligament attaching from the 2nd to 5th CSP (5/17). The absence of *lig. lamina nuchae* attachments to the 7th CSP in extant species suggests that the small percentage (2/27, or 7%) of pre-domesticated *Equus* exhibiting a scalenate 7th CSP also lacked this attachment. Even so, the museum specimens were more robust and the entheses patterns, if present, would require further research to identify a differing *lig. lamina nuchae* morphology or other influential factors, such as the maturity of the specimen.

As is the case with the 6th CSP, a truncate 7th CSP is present only in the museum specimens 7/27 (26%). Since this profile is absent in extant species, the significance of this finding is not yet known; however, the number of specimens present in the museum specimens may be indicative of another species of *Equus* either known or unknown, or a differing *lig. lamina nuchae* morphology yet to be identified.



**Figure 5.** Morphological profile of the 7th cervical spinous processes in four extant species (n=33) and museum specimens (n=27) of *Equus*. \*indicates straight cranial margin, apex, and concave caudal margin (representational of falcate and scalenate profiles).

Specific identification of *Equus* material held in museum collections has long been a source of consternation for paleontologists; many specimens are labeled simply as ‘*Equus* species?’. This is primarily the result of similar morphology amongst species of *Equus* and reports of overlapping geographical ranges (Orlando et al 2006). Additionally, complications arise when provenance is lost and disarticulated specimens are retrieved during fishing and dredging techniques, especially in relation to European specimens retrieved from the North Sea (Mol et al. 2006; Lyman 2012).

The long blade-like CSP in early perissodactyls appears to be correlated to a feeding regime that involved browsing. This is still evident in two extant perissodactyl genera (Tapiridae and Rhinocerotidae) (MacFadden 1992; Wood et al. 2011; Zsoldos and Licka 2015, Arnold 2020). However, in Equidae, the reduction of CSPs is correlated with a reduction in mechanical constraints on cervical mobility (Denoix 1999). This allows for increased potential for lateroflexion and rotation of the neck in comparison with *Hyracotherium*, in which dorsoventral flexion predominates (Denoix 1999; Wood et al. 2012). The reduced condition of the CSPs in most extant *E. caballus* that is correlated with a reduction of the *lig. lamina nuchae* from the 6th and 7th CSPs is not exhibited in fossil *E. caballus*, suggesting that this ligament attached to all the relevant CSPs from the 2nd to 7th in pre-domestication horses; however, this would require further investigation. Even so, the current study presented morphological findings of the 6th and 7th CSP profiles that might assist paleontologists in specific identification of disarticulated and/or dissociated *Equus*, as well as inferring the specific morphology of the *lig. lamina nuchae* in fossil *Equus*.

## ACKNOWLEDGMENTS

The authors wish to thank Kristen Brabender, Hortabagy National Park, Hungary, for her assistance with Przewalski horses; Wildlands Zoo for their assistance in a Grant’s Zebra, Emmen, Netherlands; The Australian College of Equine Podiotherapy for the use of its facilities. Further acknowledgements must be extended to those curators and collection managers of fossil *Equus* specimens in the following Museums: Dr. Aisling Farrell – Rancho La Brea Tarpits, Los Angeles USA; Professor Lars Werdelin – Swedish Museum of Natural History; Mr. Bram Langeveld – Natuurhistorisch Museum, Rotterdam Netherlands; Dr. Thomas Schossleitner – Berlin Natural History Museum, Germany; and Dr. Elaine Turner – Monrepus Archaeological Research Centre and Museum for Human Behavioural Evolution, Neuwied Germany, and to those authors/editors/publishers of those articles, journals and books cited in this manuscript.

## LITERATURE CITED

- Arnold, M.A. Arnold’s Glossary of Anatomy. The University of Sydney, Anatomy and Histology. <https://anatomy.usyd.edu.au/glossary/index.cgi> Retrieved 12th March 2021.
- Arnold, P. 2020. Evolution of the mammalian neck and development, morpho-functional, and paleontological perspectives. *Journal of Mammalian Evolution*. DOI 10.1007/s10914-020-09506-9.
- Arnold, P., E. Amson, and M.S. Fischer. 2017. Differential scaling patterns of vertebrae and the evolution of neck length in mammals. *Evolution* 71:1587–1599.
- Brown, K.E., W.A. Akersten, and E. Scott. 2015. *Equus occidentalis* Leidy from “Asphalto” Kern County, California. *Science Series* 42:81–99.
- Buchholtz, E.A., H.D. Bailin, S.A. Laves, J.T. Yang, M-Y. Chan, and L.E. Drozd. 2012. Fixed cervical count and the origin of the mammalian diaphragm. *Evolution and Development* 14:399–411.
- Denoix, J-M. 1999. Spinal biomechanics and functional anatomy. *Veterinary Clinics of North America: Equine Practice* 15:27–60.
- Dunbar, D.C., J.M. Macpherson, R.W. Simmons, and A. Zarcades. 2008. Stabilization and moonily of the head, neck and trunk in horses during over-ground locomotion; comparisons with humans and other primates. *Journal of Experimental Biology* 211:3889–3907.
- Gasse, H., W. Van Den Broeck, and P. Simeons. 2017. *Nomina Anatomica Veterinaria*. 6th ed. Published by the Editorial Committee for the World Association of Veterinary Anatomists. Hanover, Ghent, Columbia MO and Rio de Janeiro. 160 pp.
- Geigl, E-M. and T. Grange. 2012. Eurasian wild asses in time and space: Morphological versus genetic diversity. *Annals of Anatomy* 194:88–102.
- Gellman, K.S. and J.E.A. Bertram. 2002. The equine nuchal ligament 2: passive dynamic energy exchange in locomotion. *Veterinary and Comparative Orthopaedics and Traumatology* 1:7–14.
- Getty, R. 1975. Equine osteology; pp. 255–348 in S. Sisson, and J.D. Grossman (eds.), *The Anatomy of Domestic Animals*. Saunders, Philadelphia USA.
- Haussler, K.K. June 2016. Functional anatomy and clinical biomechanics of the equine cervical spine. Paper presented at the AAEP Conference 360° Pain in the Neck, Fort Collins Colorado.
- Lyman, R.L. 2012. A historical sketch on the concepts of archaeological association, context and provenience. *Journal of Archaeological Method and Theory* 19:207–240.
- MacFadden, B.J. 1992. *Fossil Horses: Systematics, Paleobiology, and Evolution of the Family Equidae*. Cambridge University Press. Cambridge UK. 367 pp.
- May-Davis, S. and J. Kleine. 2014. Variations and implications of the gross anatomy in the equine nuchal ligament lamellae. *Journal of Equine Veterinary Science* 34:1110–1113.

- May-Davis, S., W.Y. Brown, and Z. Vermeulen. 2018. The disappearing lamellae: implications of new findings in the family Equidae suggest the loss of nuchal ligament lamellae on C6 and C7 occurred after domestication. *Journal of Equine Veterinary Science* 68:108–114.
- May-Davis, S., R. Hunter, and W.Y. Brown. 2020a. A comparative morphological study of the *ligamentum lamina nuchae* and *ligamenta interspinalia* reveals entheses patterns at the sites of attachment from the second to seventh cervical vertebrae in four extant species of *Equus*. *Vertebrate Anatomy Morphology Palaeontology* 8:170–181.
- May-Davis, S., F. Minowa, and W.Y. Brown. 2020b. An in situ and ultrasound study of Yonaguni ponies revealed the rare finding of the nuchal ligament lamellae from C2–C7. *Journal of Equine Science* 31:93–94.
- May-Davis, S., Z. Vermeulen, R. Hunter, and W. Brown. 2020c. Rare finding of a full nuchal ligament lamellae with attachment points from C2–C7 in one Australian Stock Horse. *Journal of Equine Veterinary Science* 84:102847.
- Mol, D., K. Post, J.W.F. Reumer, J. van der Plicht, J. de Vos, B. van Geel, G. van Reenen, J.P. Pals, and J. Glimmerveen. 2006. The Eurogeal – first report of the palaeontological, palynological and archaeological investigations of this part of the North Sea. *Quaternary International* 142–143:178–185.
- Muir, J. 1871. The Malayan tapir. *Journal of Anatomy and Physiology* 6:131–172.
- Nussey, D.H., A.J. Wilson, and J.E. Brommer. 2007. The evolutionary ecology of individual phenotypic plasticity in wild populations. *Journal of Evolutionary Biology* 20:831–844.
- Orlando L., M. Mashkour, A. Burke, C.J. Douady, V. Eisenmann, and C. Hanni. 2006. Geographic distribution of an extinct equid (*Equus hydruntinus*: Mammalia, Equidae) revealed by morphological and genetical analyses of fossils. *Molecular Ecology* 15:2083–2093.
- Pellow, B.J., M.J. Henwood, and R.C. Carolin. 2010. eFlora: Vascular plants of the Sydney region. The University of Sydney (5th ed). Retrieved 12th March 2021.
- Schmaltz, R. 1924. Atlas der Anatomie des Pferdes. Verlagsbuchhandlung von Richard Schoetz: Berlin Germany. Plate 17b.
- Singh, B. 2018. Dyce, Sack and Wensing's Textbook of Veterinary Anatomy. Elsevier, Missouri, USA. 1606 pp.
- Sisson, S. 1910. A Textbook of Veterinary Anatomy. W.B. Saunders, Philadelphia, USA. 724 pp.
- Sisson, S. 1953. Equine syndesmology; pp. 209–246 in S. Sisson and J.D. Grossman (eds.), *The Anatomy of Domestic Animals*. Fourth edition. W.B. Saunders, Philadelphia USA.
- Sisson, S. 1975. Equine syndesmology; pp. 349–375 in S. Sisson and J.D. Grossman (eds.), *The Anatomy of Domestic Animals*. Fifth edition. W.B. Saunders, Philadelphia, USA.
- Wood, A.R., R.M. Bebej, C.L. Manz, D.L. Begun, and P.D. Gingerich. 2011. Postcranial functional morphology of *Hyracotherium* (Equidae, Perissodactyla) and locomotion in the earliest horses. *Journal of Mammalian Evolution* 18:1–32.
- Zsoldos, R.R. and T.F. Licka. 2015. The equine neck and its function during movement and locomotion. *Zoology* 118:364–376.